

LETTER TO THE EDITOR

WILEY

Congenital cutaneous mastocytosis mistaken for non-accidental injury

To the editor:

A previously well male infant presented to his general practitioner (GP) for his routine 6-week check. His parents reported the presence of tan-brown lesions since birth. The marks were uniform in color, were present on the trunk, scalp, and face, and were not overlying bony prominences. The GP was concerned that these lesions represented bruising as a manifestation of non-accidental injury (NAI), and arranged an urgent review at our pediatric department. Following assessment by the pediatric team he was admitted for investigation of potential NAI, and dermatology consultation was sought. On examination, scattered reddish brown to tan macules and papules were noted on the torso and limbs, not overlying bony prominences (Figure 1A, B). Darier's sign was negative, although some reactive cutis marmorata was appreciable on the trunk following the rubbing of multiple lesions. A diagnosis of urticaria pigmentosa (UP), now known as maculopapular cutaneous mastocytosis (CM), a form of CM, was made clinically. Skin biopsies demonstrated an infiltrate of spindled and round mast cells and scattered eosinophils within the superficial and mid dermis, with immunohistochemistry positive for CD117, consistent with CM (Figure 1C–E). Blood tests during admission showed a normal complete blood count and coagulation screen (including von Willebrand factor), normal renal and liver function, normal lactate dehydrogenase, normal immunoglobulins, and normal mast cell tryptase. Cranial ultrasound and abdominal ultrasound (including liver and spleen) were normal.

Mastocytosis is a spectrum of disease characterized by the pathologic accumulation of mast cells in tissues, including skin, bone marrow, and the gastrointestinal tract. The World Health Organisation has outlined three variants: CM, systemic mastocytosis, and mast cell sarcoma. CM can be further classified as maculopapular CM, also known as

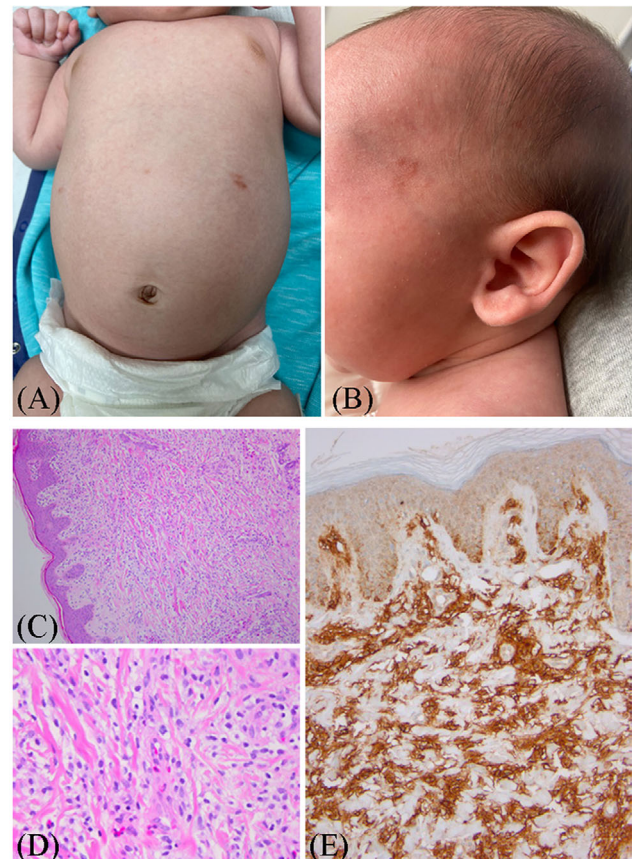


FIGURE 1 Macroscopic, histological, and immunohistochemical findings of the boy with urticaria pigmentosa. (A) Subtle isolated red-brown to tan macules present on the abdomen. (B) A red-brown plaque overlying the left temple. (C) A skin biopsy from the back with a cellular infiltrate in the dermis composed of mast cells and scattered eosinophils on Hematoxylin and eosin (H&E) staining (original magnification $\times 10$). (D) Higher power (original magnification $\times 40$) H&E staining of the mast cells and eosinophils within the dermis. (E) Immunohistochemistry for CD117 which stains mast cells and highlights the mast cell infiltrate in the dermis (original magnification $\times 20$).

DOI: 10.1002/ped4.12370

This is an open access article under the terms of the Creative Commons Attribution-NonCommercial-NoDerivs License, which permits use and distribution in any medium, provided the original work is properly cited, the use is non-commercial and no modifications or adaptations are made.

© 2023 Chinese Medical Association. *Pediatric Investigation* published by John Wiley & Sons Australia, Ltd on behalf of Futang Research Center of Pediatric Development.

UP; diffuse CM; and localized cutaneous mastocytomas.¹ Pediatric CM is regarded as a benign condition limited to skin, most commonly presenting as UP, which usually spontaneously regresses in puberty.² In contrast, adult-onset mastocytosis is more often associated with systemic involvement, a persistent course, and activating mutations of the *KIT* gene.¹

With UP, children typically present in the first two years of life with multiple reddish-brown macules, papules, and/or plaques distributed anywhere on the body, most commonly the trunk. In darkly pigmented skin, lesions may be hyperpigmented and erythema less appreciable. Darier sign, a transient urticarial response upon gentle rubbing of the skin, is classic and supportive of the diagnosis, though not always demonstrable. Treatment with antihistamines can be helpful.³ UP has rarely been reported to be misdiagnosed as NAI.^{4,5} Other 'bruising' mimics include disorders of coagulation, Valsalva petechiae, vasculitis, acute hemorrhagic edema, incontinentia pigmenti, phytophotodermatitis, coin rubbing, spooning, cupping, Mongolian spots, morphea, neuroblastoma, and ink stains, some of which may be unfamiliar to pediatricians or dermatologists.⁵ CM can be differentiated from bruising by the typically monomorphic appearance; the persistence of lesions with very gradual resolution; the development of new lesions without trauma; the presence of lesions on any part of the body, not specifically overlying bony prominences; the presence of itch; and the presence of Darier sign. Dermatologists have a crucial role in recognizing cutaneous manifestations of NAI in children, which commonly includes bruising, particularly in infants who are not yet mobile.⁴ While consideration of NAI is important in all children presenting for medical care, this case highlights the importance of considering underlying dermatoses to avoid unwarranted distress and unnecessary investigations.

Emma Porter¹, Cynthia Heffron², Lesley Ann Murphy¹,
Cathal O'Connor^{1,3} 

¹Department of Dermatology, South Infirmery Victoria University Hospital, Cork, Ireland

²Department of Pathology, Cork University Hospital, Cork, Ireland

³INFANT Research Centre, University College Cork, Cork, Ireland

Correspondence

Cathal O'Connor, Department of Dermatology, South Infirmery Victoria University Hospital, Cork, Ireland.
Email: cathal.oconnor@ucc.ie

CONSENT FOR PUBLICATION

Written informed consent was obtained from the patient's parent.

CONFLICT OF INTEREST

None.

REFERENCES

1. Valent P, Akin C, Metcalfe DD. Mastocytosis: 2016 updated WHO classification and novel emerging treatment concepts. *Blood*. 2017;129:1420-1427. DOI: 10.1182/blood-2016-09-731893
2. Hartmann K, Escribano L, Grattan C, Brockow K, Carter MC, Alvarez-Twose I, et al. Cutaneous manifestations in patients with mastocytosis: consensus report of the European Competence Network on Mastocytosis; the American Academy of Allergy, Asthma & Immunology; and the European Academy of Allergology and Clinical Immunology. *J Allergy Clin Immunol*. 2016;137:35-45. DOI: 10.1016/j.jaci.2015.08.034
3. Schaffer JV. Pediatric mastocytosis: recognition and management. *Am J Clin Dermatol*. 2021;22:205-220. DOI: 10.1007/s40257-020-00581-5
4. Patel B, Butterfield R. Common skin and bleeding disorders that can potentially masquerade as child abuse. *Am J Med Genet C Semin Med Genet*. 2015;169:328-336. DOI: 10.1002/ajmg.c.31462
5. Ramphul N, Harikrishnan S, Harikumar C, Carmichael AJ. Urticaria pigmentosa masquerading as non-accidental injury. *Arch Dis Child*. 2015;100:850. DOI: 10.1136/archdischild-2014-307915

How to cite this article: Porter E, Heffron C, Murphy LA, O'Connor C. Congenital cutaneous mastocytosis mistaken for non-accidental injury. *Pediatr Investig*. 2023;00:1-2. <https://doi.org/10.1002/ped4.12370>