

ORIGINAL ARTICLE

Pattern of regional recurrence after selective neck dissection for clinically positive neck in mucosal squamous carcinoma

Mohammad Altawil MB, FRCSI (ORL-HNS)¹ | Isabella Stanisz MD¹ |
Nadia H. Van Den Berg MB¹ | Patrick Sheahan MD, FRCSI (ORL-HNS)^{1,2} 

¹Department of Otolaryngology – Head & Neck Surgery, South Infirmar Victoria University Hospital, Cork, Ireland

²ENTO Research Unit, College of Medicine and Health, University College, Cork, Ireland

Correspondence

Nadia Van Den Berg and Patrick Sheahan, Department of Otolaryngology – Head & Neck Surgery, South Infirmar Victoria University Hospital, Cork, Ireland.

Email: nadia9559@gmail.com; patrick.sheahan@ucc.ie; sheahan.patrick@sivuh.ie

Section Editor: Benjamin Judson

Abstract

Background: Selective neck dissection (SND) has traditionally been applied to clinically negative (cN0) necks in mucosal squamous cell carcinoma (SCC). We aimed to examine the oncological safety and patterns of regional recurrence (RR) of SND in clinically positive (cN+) necks.

Methods: Retrospective review of prospective cohort of 206 patients with mucosal SCC undergoing neck dissection. RR was classified as occurring within previously dissected levels, within ipsilateral undissected levels, within unusual locations of ipsilateral neck, or contralateral neck.

Results: Seven of seventy-seven (9.1%) cN+ patients undergoing SND developed isolated RR, versus 16.2% after MRND, and 8.7% after SND for cN0 disease. RR was rarely seen within undissected levels of the ipsilateral neck. RR and survival rates were not associated with ND extent (SND vs. MRND) among either cN+ or pN+ patients.

Conclusion: SND can be safely performed in most patients with cN+ SCC, who do not have gross sternocleidomastoid infiltration or level V metastases.

KEYWORDS

neck dissection, recurrence, selective neck dissection, squamous cell carcinoma

1 | INTRODUCTION

Historically, radical neck dissection (RND), or its modifications of modified radical neck dissection (MRND) or comprehensive/functional neck dissection, encompassing removal of all cervical lymph nodes from cervical levels I-V, were described as being effective surgical strategies

for patients with clinically positive neck disease (cN+) from head and neck mucosal squamous cell carcinoma (SCC)^{1–3}; with selective neck dissection (SND), encompassing removal of only cervical levels containing lymph nodes at highest risk of harboring metastases, reserved for patients with clinically negative necks (cN0).⁴ In 1990, Shah showed that the incidence of metastases to level V was low, even among patients with established nodal metastases in levels II/III, basing his report on a series of 1119 RNDs for head and neck SCC, of which

The results of this paper have been previously partly presented at the Irish Head and Neck Society Meeting, Kilkenny, Ireland, 2022.

This is an open access article under the terms of the [Creative Commons Attribution](https://creativecommons.org/licenses/by/4.0/) License, which permits use, distribution and reproduction in any medium, provided the original work is properly cited.

© 2024 The Authors. *Head & Neck* published by Wiley Periodicals LLC.

776 were for cN+ disease.⁵ This paper led to the evolution of surgical strategies involving use of SND among selected cN+ patients with low volume nodal metastases.^{6–10} Benefits of SND include avoidance of dissection of the accessory nerve in the posterior triangle, with resultant reduction in shoulder morbidity; preservation of sternocleidomastoid (SCM) muscle, with improved postoperative neck contour and coverage of carotid artery; and reduced overall extent of dissection in the neck which may reduce post-treatment fibrosis and lymphoedema.^{11,12} However, most data on the safety of SND on patients with cN+ disease is based on retrospective data, with analysis of outcomes often performed based on pathological nodal status (pN+), which thus may be biased by inclusion of patients with cN0pN disease undergoing elective ND. Furthermore, it is unclear which patients are most suitable for a SND approach to cN+ disease, with conclusions of most authors being that this approach should be reserved for carefully selected cases.^{6,8,13}

In our practice, patients with cN+ necks generally undergo SND as the default option, unless there is radiological evidence of invasion of sternocleidomastoid muscle (SCM) or posterior triangle metastases. The aim of this study was to study the pattern of RR after SND among patients with clinically positive neck disease (cN+) in our institution.

2 | METHODS

The present study was a retrospective review of a prospectively maintained database of patients undergoing surgery for mucosal SCC performed by a single surgeon (PS). Ethical approval was granted by the Cork Clinical Research Ethics Committee. Inclusion criteria for the study were patients undergoing ND for previously untreated head and neck mucosal SCC (excluding nasopharynx) between 2009 and 2019 inclusive. SCC of unknown primary site was included where this was presumed to be arising from occult mucosal primary, based on level 2/3 location, no history of skin cancer in vicinity, and non-Asian patient. Exclusion criteria were non-squamous histology, previous diagnosis of any head and neck SCC, or previous neck radiotherapy or neck surgery.

Patients with head and neck SCC at our institution nearly all underwent preoperative computed tomography (CT) and/or magnetic resonance imaging (MRI) of neck, with radiological findings discussed at multidisciplinary team (MDT) meeting. Status of the neck (cN0 or cN+) was based on outcome of preoperative clinical and radiological findings, as agreed at MDT meeting, and was documented prospectively in the Head & Neck database.

Neck levels were defined according to the schema of the American Head and Neck Society and American Academy of Otolaryngology-Head & Neck Surgery.^{14,15} For the purpose of the present study, SND was defined as ND with preservation of at least level V, +/- levels I/IV, and with preservation of SCM. Cases of level II-V dissection, or any case with resection of SCM, were considered as MRND/RND. The default strategy of the senior author was to perform SND on most cN+ patients with mucosal SCC, excepting cases of gross radiological involvement of SCM, or radiological suspicion of posterior triangle metastases. Comprehensive/functional ND were not performed by the senior author for mucosal SCC. The type of neck dissection performed, resection of other non-lymphatic structures, and surgical findings were prospectively documented at the time of surgery in the database. For the purposes of the study, patients were divided into three groups: Group 1, patients staged cN0 undergoing unilateral or bilateral SND; Group 2, patients staged cN+ undergoing unilateral or bilateral SND; and Group 3, any patients undergoing MRND or RND. Postoperatively, patients were re-discussed at MDT, and postoperative radiotherapy generally offered patients with pathologically involved nodes. Final pathology and clinical outcomes were determined by retrospective review of patient notes.

Regional recurrence (RR) was defined as recurrence of SCC anywhere in the neck during the follow up period. RR was considered to be isolated when occurring in patients who did not develop local recurrence (LR) or second primary SCC tumors (SPT) of the head and neck. Location of RR was determined by review of patient notes and radiology and was classified as follows: (1) recurrence within previously dissected neck levels; (2) recurrence in ipsilateral undissected levels, including any RR in levels V, I, or IV, where these were not dissected at the time of original ND; (3) recurrence in ipsilateral unusual locations, that is, recurrences occurring in ipsilateral areas which would not be removed as part of standard ND, including parotid gland, parapharyngeal space, or skin nodules; or (4) recurrence in contralateral undissected neck.

Statistical analysis was performed using XLSTAT (Addinsoft, France). A Fisher exact test was used on 2×2 contingency tables. Survival analysis was performed using the Kaplan–Meier method, with differences between groups analyzed using log-rank test. Hazard ratios were calculated using Cox regression modeling.

3 | RESULTS

During the study period, 206 patients with previously untreated mucosal HNSCC underwent ND as part of

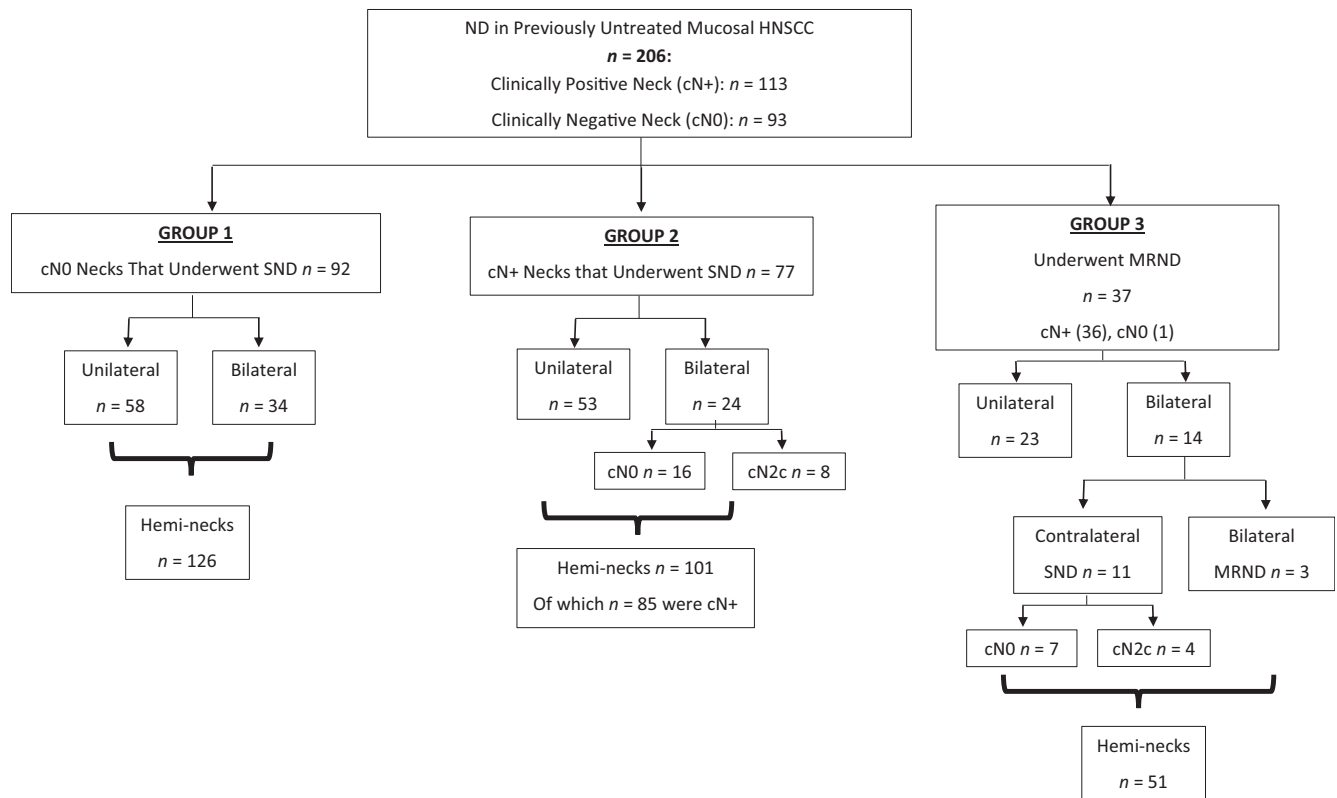


FIGURE 1 Composition of Groups 1, 2, and 3 according to laterality of neck dissection and neck status.

their primary treatment. Hundred and thirteen of 206 (54.9%) patients had cN+ disease. Among patients with cN0 disease, 92/93 underwent unilateral (58) or bilateral (34) SND (Group 1). Seventy-seven of 113 (68.1%) patients with cN+ disease were treated by SND (unilateral 53, bilateral 24) (Group 2). Among Group 2 patients undergoing bilateral neck dissection, 8/24 had bilateral clinically positive necks (cN2c), giving 85 cN+ heminecks treated by SND. Finally, 37 patients underwent MRND/RND, including 1 patient with cN0 neck who had direct infiltration of SCM by a laryngeal cancer (Group 3). Fourteen of 37 patients in Group 3 underwent bilateral ND (11/14 contralateral SND, of whom 4 had cN2c disease; and 3/14 bilateral MRND/RND) (Figure 1). Patient clinical and demographic details are given in Table 1.

Among patients in Group 2, all patients underwent dissection of levels IIA, IIB, and III. Thirty of 77 patients (all with oral cavity primaries) underwent dissection of ipsilateral level I, with 12/30 patients undergoing bilateral level I dissection. Sixty-nine of 77 patients underwent dissection of level IV (16 bilateral). Seven patients underwent resection of internal jugular vein (IJV). One patient underwent deliberate resection of hypoglossal nerve, one underwent deliberate resection of phrenic nerve, and four underwent skin resection. No patient underwent

deliberate resection of accessory nerve. In Group 3, 10/37 patients underwent resection of accessory nerve, 3/37 underwent resection of hypoglossal nerve, 28/37 underwent resection of IJV.

Among patients in Group 1 (cN0), the mean number of lymph nodes removed per hemineck was 27.1. Twenty-seven of 92 (29.3%) patients (29 heminecks) were pN+. The mean number of positive lymph nodes per hemineck was 0.5 (2.1 among pN+ patients). Nine of 92 (9.8%) patients had extracapsular spread (ECS). Among patients in Group 2 undergoing SND for cN+ disease, the mean number of lymph nodes removed was 33.8, which was significantly greater than the number of nodes removed in Group 1 ($p < 0.001$). Sixty-seven of 77 (87%) patients (71 heminecks) were pN+. The mean number of positive nodes per hemineck was 2.8 (3.5 among pN+ patients). Thirty-one of 77 (40.3%) patients had ECS. Finally, among patients in Group 3 undergoing MRND, the mean number of lymph nodes removed per hemineck was 36.8, which was not significantly different to patients in Group 2 ($p = 0.28$). Thirty-six of 37 (97%) patients (39 heminecks) were pN+. The mean number of positive nodes per hemineck was 6.0.

Among patients in Group 1, 52/92 (56.5%) underwent postoperative radiotherapy (PORT); two of whom also received postoperative chemotherapy treatment (POCRT)

TABLE 1 Demographic details.

		Group 1 (n = 92)	Group 2 (n = 77)	Group 3 (n = 37)
Sex ratio (M:F)		67:25	56:21	33:4
Age (years)	Mean (range)	62.0 (29–89)		
Primary site	Oral cavity	73	29	7
	Oropharynx	2 (2 HPV+)	28 (24 HPV+)	13 (7 HPV+)
	Larynx	16	7	5
	Hypopharynx	1	3	8
	Sinonasal	0	1	0
	Unknown	0	9 (5 HPV+)	4 (0 HPV+)
Extent of surgery	Primary site + neck	89	72 ^a	23 ^b
	Neck only	3 (delayed ND after primary resection)	5 (2 delayed ND after primary resection)	14 (1 delayed ND after primary resection)
cT stage	T0/Tx	0	18	11
	T1	30	14	2
	T2	33	23	8
	T3	10	9	7
	T4	19	13	9
cN stage	N0	92	4 (upstaged intraoperatively to N+)	1
	N1	0	37	2
	N2a	0	5	6
	N2b	0	24	19
	N2c	0	6	7
	N3	0	1	2
pT stage	T0/Tx	0	8	7
	T1	30	23	7
	T2	33	23	6
	T3	10	10	7
	T4	19	13	10
pN stage	N0	65	10	3
	N1	13	22	0
	N2a	0	6	4
	N2b	5	26	16
	N2c	2	9	5
	N3b	7	4	9

^aThis includes seven patients who underwent tonsillectomy and base of tongue mucosectomy with no primary found.

^bThis includes one patient who underwent tonsillectomy and base of tongue mucosectomy with no primary found.

(2.2%, 2/92). In Group 2, 84.4% (65/77) underwent PORT; of these 11 patients received combined POCRT (14.3%, 11/77). Among patients in Group 3, 31/37 (83.8%) received PORT with 12 patients receiving combined treatment (12/37, 32.4%).

Mean follow-up was 47 (median 40) months. Regional recurrence (RR) occurred in 37/206 (18.0%) patients. In

16/37 patients, RR occurred simultaneous with or subsequent to local recurrence (LR) (12) or emergence of second primary tumor (SPT) (4). Thus, 21/37 patients had isolated RR, developing a mean of 15 (median 9) months after ND.

Among patients in Group 1, 11/92 patients developed regional recurrence. Eight of 92 (8.7%) patients

TABLE 2 Patterns of regional recurrence according to group.

	Group 1		Group 2		Group 3		Total
	Isolated RR, <i>n</i> = 8	RR after LR/SPT, <i>n</i> = 3	Isolated RR, <i>n</i> = 7	RR after LR/SPT, <i>n</i> = 9	Isolated RR, <i>n</i> = 6	RR after LR/SPT, <i>n</i> = 4	
Within previously dissected levels	5	1 ^a	5	3	2	3 ^a	19
Within ipsilateral undissected levels	1			1			2
Within ipsilateral unusual locations	1			1	4		6
Contralateral undissected neck	1	3 ^a	2	4		2 ^a	12
Total	8	4 ^a	7	9	6	5 ^a	39

^aOne patient had simultaneous RR within previously dissected levels and contralateral neck.

developed isolated RR (6.3% of heminecks 8/126). Five of these were pathologically negative at the time of initial ND, and four occurred in patients who had undergone postoperative irradiation. The incidence of isolated RR among cN0pN+ patients was 11.1% (3/27). Isolated RR in Group 1 occurred within previously dissected levels in 5/8 patients, in ipsilateral undissected levels (supraclavicular fossa) in 1/8 patient, in ipsilateral unusual location (parapharyngeal space) in 1/8 patient, and in the contralateral undissected neck in 1/8 patient. In addition, three further patients developed RR after LR (2) or development of SPT (1). These recurrences occurred in the contralateral neck in two patients, and in previously dissected levels plus contralateral neck in one patient.

Among patients in Group 2, 7/77 (9.1%) patients developed isolated RR, all occurring in pN+ patients (7/67, 10.4%). Seven of 85 (8.2%) of cN+ heminecks undergoing SND developed isolated RR. RR occurred within previously dissected levels in 5/7 patients, and in the contralateral undissected neck in 2/7 patients. All isolated RR occurred in irradiated patients. In addition, nine further patients developed RR after LR (6) or SPT (3). These recurrences occurred within previously dissected levels in 3/9 patients, ipsilateral undissected levels (supraclavicular fossa) in 1/9 patient, ipsilateral unusual location (parotid gland) in 1/9 patient, and contralateral undissected neck in 4/9 patients.

Finally, among patients in Group 3, there were 6/37 cases of isolated RR (16.2%), of which 2/6 were in previously dissected levels, and 4/6 were in ipsilateral unusual locations (two parapharyngeal space, two skin nodules). All isolated RR occurred in irradiated patients. The incidence of isolated RR per cN+ hemineck undergoing MRND was 15.4% (6/39). There were 4/10 further cases of RR after LR, which occurred in previously dissected levels (2), contralateral undissected neck (1), and

previously dissected levels + contralateral undissected neck (1). Patterns of RR among all three groups is shown in Table 2 and Figure 2.

3.1 | Survival

Among the entire cohort, there was no difference in RR according to group (Figure 3). There were significant differences between the three groups for OS ($p = 0.004$), with patients in Group 1 and Group 2 ($p = 0.004$) having significantly better OS than patients in Group 3. There was no difference in OS between patients in Group 1 and Group 2 ($p = 0.85$).

Due to the likely bias of survival results due to HPV-associated cancers, the survival analysis was repeated with exclusion of HPV-related cancers. Although patients in Group 3 had a higher incidence of RR, the differences between the three groups did not reach significance ($p = 0.07$). For OS, there were significant differences between the groups ($p = 0.0002$). Patients in Group 1 had better OS than patients in Group 2 ($p = 0.01$). Differences between Group 2 and Group 3 were not significant ($p = 0.15$), indicating that extent of ND was not a risk factor for RR or OS in patients with cN+ necks (Figure 4).

Among cN + pN+ patients who were HPV-negative, performance of SND versus (MRND/RND) had no impact on risk of isolated RR (HR 1.04, 95% CI 0.35, 3.10) or OS (HR 1.06, 95% CI 0.62, 1.81) (Figure 5).

3.2 | Complications

Complications are shown in Table S1, Supporting Information. The incidence of complications was 8.7% (8/92)

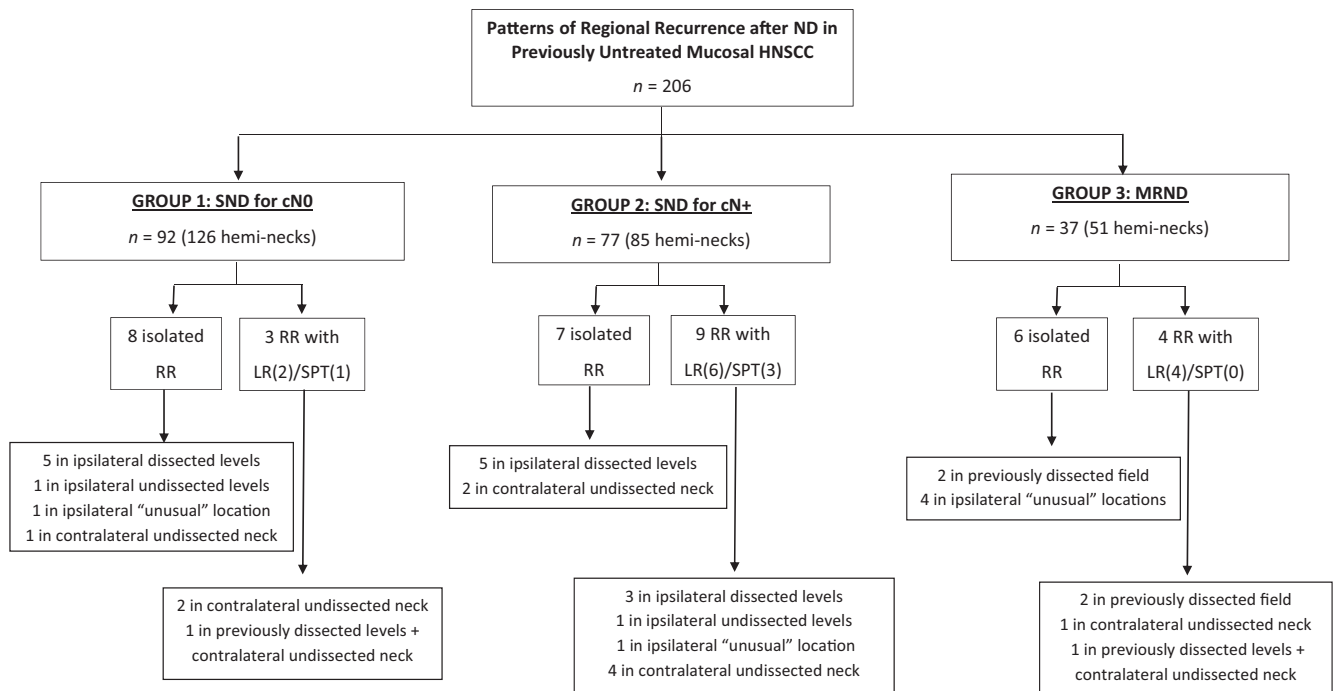


FIGURE 2 Patterns of RR according to group.

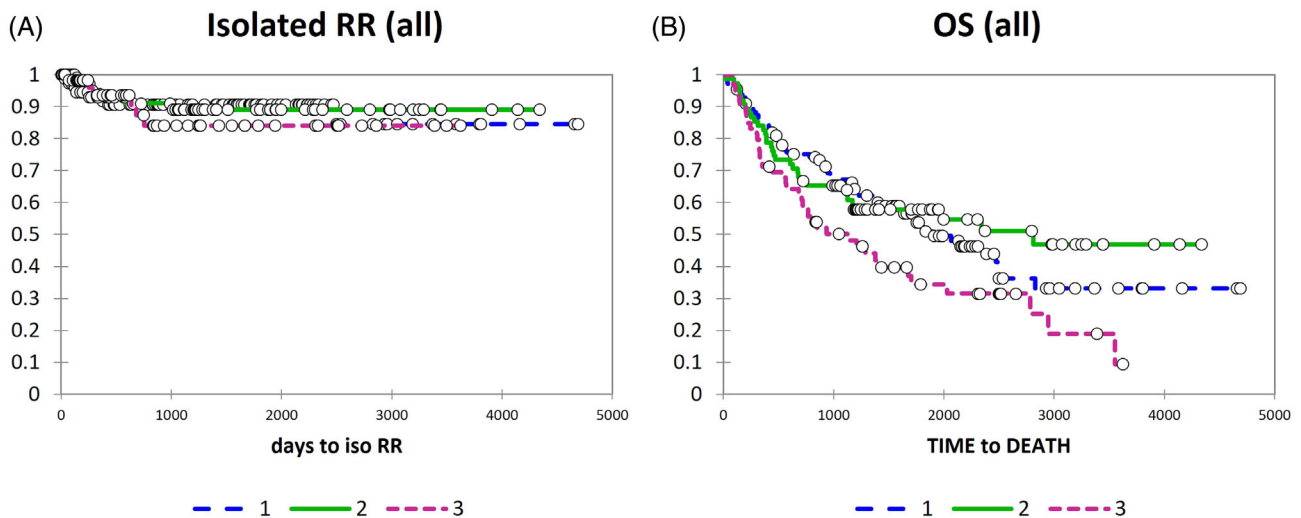


FIGURE 3 Kaplan-Meier curves for isolated regional recurrence (A) and overall survival (B) among entire cohort, according to group. [Color figure can be viewed at wileyonlinelibrary.com]

in Group 1, 11.7% (9/77) in Group 2, and 16.2% (6/37) in Group 3. Excluding complications related to the primary tumor resection, the incidence of complications was 4.4% (4/92) in Group 1, 3.9% (3/77) in Group 2, and 8.1% (3/37) in Group 3.

4 | DISCUSSION

In the present study, we found the incidence of isolated RR after SND for cN+ disease to be comparable to that

among cN0 patients undergoing SND, and less than that seen among patients undergoing MRND. In addition, when RR did occur, this most commonly occurred within previously dissected levels, or in the undissected contralateral neck, and rarely occurred within undissected levels of the ipsilateral neck. This held true even for patients who developed RR after LR or SPT. These findings would suggest that SND among most cN+ patients with head and neck mucosal SCC is safe, provided there is not gross involvement of posterior triangle nodes or infiltration of sternomastoid muscle.

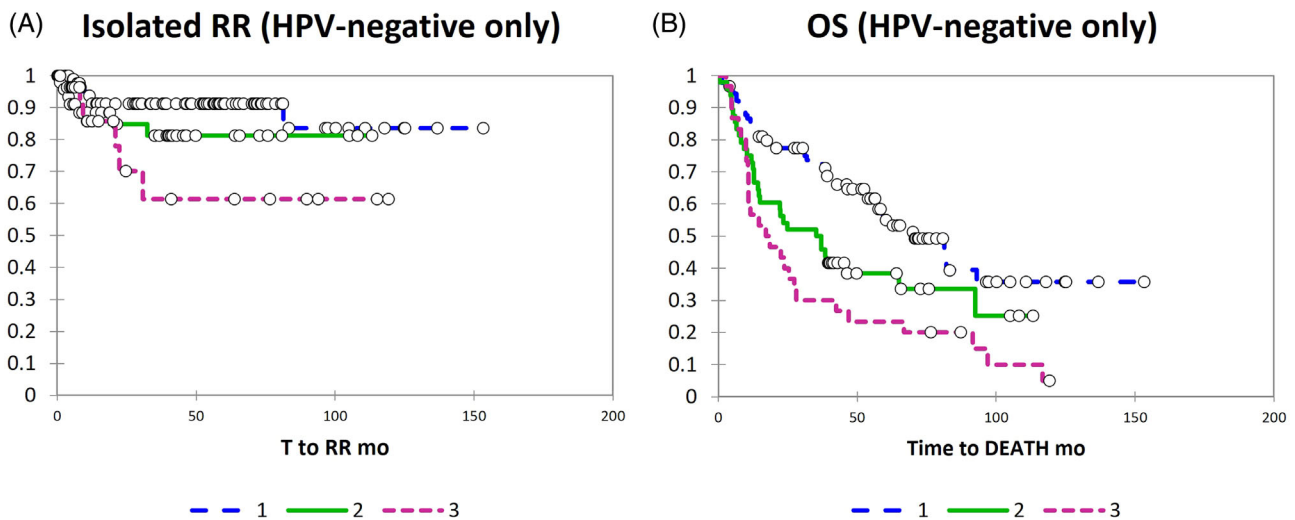


FIGURE 4 Kaplan–Meier curves for isolated regional recurrence (A) and overall survival (B) after exclusion of HPV-positive cases, according to group. [Color figure can be viewed at wileyonlinelibrary.com]

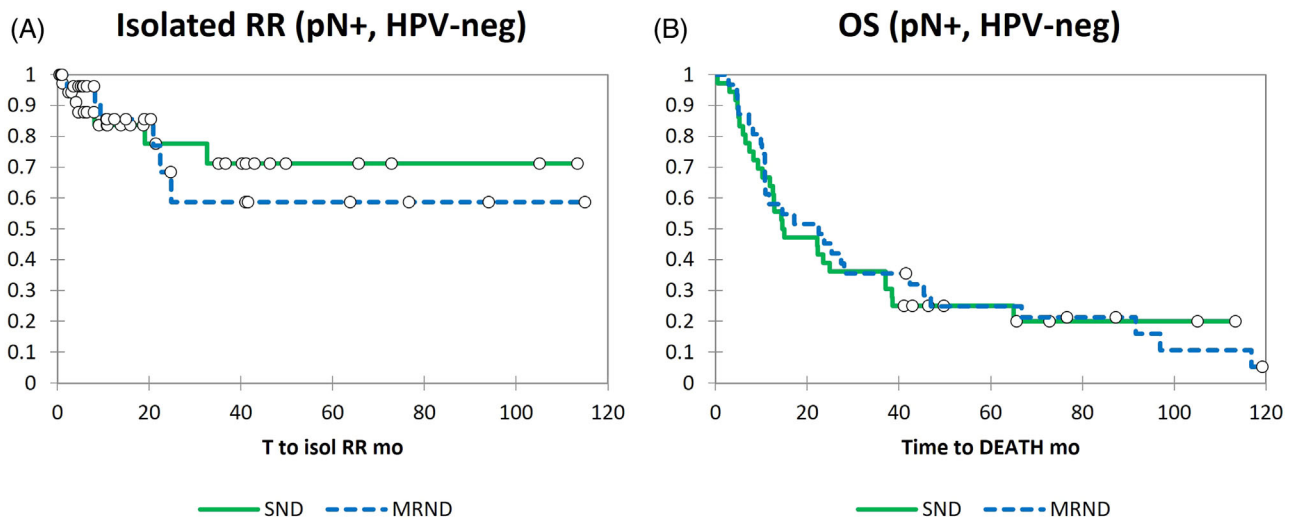


FIGURE 5 Kaplan–Meier curves for isolated regional recurrence (A) and overall survival (B) among pN+, HPV-negative patients, according to extent of neck dissection (SND vs. MRND). [Color figure can be viewed at wileyonlinelibrary.com]

Previous authors have also reported on the feasibility of SND in the N+ neck, however, most of the data are retrospective, and, in many cases, analysis of outcomes was based on pN status rather than cN status, which may have led to inclusion of large numbers of patients who were cN0.⁷ Among authors who reported specifically on outcomes of SND among patients with cN+ disease, Patel et al. reported on 233 NDs in 181 patients, of whom 71 underwent SND. RR occurred in 19%. The authors did not give the site of RR but did report only one recurrence to have occurred outside the dissected levels of the neck.⁶ Givi et al. reported 6 cases of ipsilateral RR without LR among 108 patients undergoing SND for cN+ necks, but information regarding whether these recurrences

happened within or outside previously dissected levels is not given.¹³ Shepard et al. reported two isolated RR in the ipsilateral neck among 61 cN+ patients undergoing SND, with both recurrences occurring in previously dissected levels.¹⁶ Lopez et al. reported isolated RR in 10 patients among a retrospective series of 159 patients with non-oral primaries undergoing SND.¹⁰ In a systematic review of studies on SND for cN + pN+ patients, Rodrigo et al. reported a mean neck control rate of 91% \pm 6.5% among patients; however, there may be some bias as the largest included study analyzed outcomes according to pathological rather than clinical nodal status, and so likely included cN0pN+ cases.⁹ Finally, a meta-analysis including five studies comparing outcomes of

SND to comprehensive ND, limited to patients with oral SCC, showed no difference in RR rates according to type of neck dissection.¹⁷

The use of SND among patients with cN+ clearly requires appropriate patient selection. However, it is unclear what the limits of SND in cN+ patients are. Previous authors have suggested that SND should be reserved only for patients with cN1 disease, or otherwise very low volume neck disease. In the present study, we did not limit ourselves to only low volume neck disease, in fact we performed SND as default except in cases where there was gross involvement of sternomastoid muscle or radiological suspicion of posterior triangle metastases. This is illustrated by over two-thirds of cN+ patients in the present series undergoing SND, which is a higher proportion than that reported in other studies.^{6,16,18} Compared to other studies, ours also had a higher mean number of positive nodes per pN+ hemineck (3.5),^{10,13} and greater proportion of patients with ECS (46.3%, 31/67).^{6,8–10,13,18} Therefore, our study may provide broadened indications of SND in cN+ patients.

Some caution should be exercised in generalizing the results of our study. Although data was collected prospectively, this was a retrospective study and so subject to bias associated with retrospective reviews. Second, all patients in the present series underwent radiological neck staging, with preoperative MDT discussion, which is essential to select patients for SND. Third, there are likely to be differences in surgical technique and extent of surgery between SND performed for cN+ and cN0 patients. For example, level IIB was always removed among cN+ patients. There may also have been a tendency for the surgeon to take the level of dissection further posteriorly than in cases with cN0 neck. These differences may be reflected in the higher nodal yield for SND among cN+ patients in the present study. Fourthly, most patients with pN+ disease in the present study underwent postoperative radiotherapy; thus, our findings of low RR among pN+ patients may not be applicable to patients not receiving radiotherapy. Fifth, the inclusion of cases of HPV-associated oropharyngeal SCC may have biased our results due to inclusion of cases with inherently more favorable biology and lower risk of recurrence. However, to mitigate this, we repeated the survival analysis after exclusion of HPV-positive patients and found again no difference in RR or OS outcomes among cN+ patients according to extent of ND. Finally, we did not prospectively measure shoulder function or other functional outcomes in our patients undergoing ND; however, the benefits for shoulder function of SND or MRND or RND have previously been well documented.^{11,12}

On the other hand, strengths of the paper include prospective determination and documentation of clinical

neck status and extent and type of surgery performed, the careful documentation and presentation of the site of recurrence among RR cases, as well as the less rigorous selection criteria applied to patients with cN+ disease for surgical management with SND.

5 | CONCLUSION

In the present study, we report low RR rates and good oncologic outcomes among patients with head and neck mucosal SCC with cN+ staged necks undergoing SND with postoperative radiotherapy. Our data would support consideration of SND for most patients with cN+ necks excepting cases of gross invasion of SCM or radiological suspicion of posterior triangle metastases.

ACKNOWLEDGMENT

Open access funding provided by IReL.

CONFLICT OF INTEREST STATEMENT

The authors declare no conflicts of interest.

DATA AVAILABILITY STATEMENT

The data that support the findings of this study are available on request from the corresponding author. The data are not publicly available due to privacy or ethical restrictions.

ORCID

Patrick Sheahan  <https://orcid.org/0000-0002-9153-8951>

REFERENCES

- Crile G. Landmark article Dec 1, 1906: excision of cancer of the head and neck. With special reference to the plan of dissection based on one hundred and thirty-two operations. By George Crile. *Jama*. 1987;258(22):3286-3293. doi:[10.1001/jama.258.22.3286](https://doi.org/10.1001/jama.258.22.3286)
- Bocca E, Pignataro O. A conservation technique in radical neck dissection. *Ann Otol Rhinol Laryngol*. 1967;76(5):975-987. doi:[10.1177/000348946707600508](https://doi.org/10.1177/000348946707600508)
- Lingeman RE, Helmus C, Stephens R, Ulm J. Neck dissection: radical or conservative. *Ann Otol Rhinol Laryngol*. 1977;86(6):737-744. doi:[10.1177/000348947708600604](https://doi.org/10.1177/000348947708600604)
- Brazilian Head and Neck Cancer Study Group. Results of a prospective trial on elective modified radical classical versus supraomohyoid neck dissection in the management of oral squamous carcinoma. *Am J Surg*. 1998;176(5):422-427. doi:[10.1016/s0002-9610\(98\)00230-x](https://doi.org/10.1016/s0002-9610(98)00230-x)
- Shah JP. Patterns of cervical lymph node metastasis from squamous carcinomas of the upper aerodigestive tract. *Am J Surg*. 1990;160(4):405-409. doi:[10.1016/s0002-9610\(05\)80554-9](https://doi.org/10.1016/s0002-9610(05)80554-9)
- Patel RS, Clark JR, Gao K, O'Brien CJ. Effectiveness of selective neck dissection in the treatment of the clinically positive neck. *Head Neck*. 2008;30(9):1231-1236. doi:[10.1002/hed.20870](https://doi.org/10.1002/hed.20870)

7. Ambrosch P, Kron M, Pradier O, Steiner W. Efficacy of selective neck dissection: a review of 503 cases of elective and therapeutic treatment of the neck in squamous cell carcinoma of the upper aerodigestive tract. *Otolaryngol Head Neck Surg.* 2001;124(2):180-187.
8. Andersen PE, Warren F, Spiro J, et al. Results of selective neck dissection in management of the node-positive neck. *Arch Otolaryngol Head Neck Surg.* 2002;128(10):1180-1184. doi:10.1001/archotol.128.10.1180
9. Rodrigo JP, Grilli G, Shah JP, et al. Selective neck dissection in surgically treated head and neck squamous cell carcinoma patients with a clinically positive neck: systematic review. *Eur J Surg Oncol.* 2018;44(4):395-403. doi:10.1016/j.ejso.2018.01.003
10. López F, Fernández-Vañes L, García-Cabo P, et al. Selective neck dissection in the treatment of head and neck squamous cell carcinoma patients with a clinically positive neck. *Oral Oncol.* 2020;102:104565. doi:10.1016/j.oraloncology.2020.104565
11. Rajendra Prasad B, Sharma SM, Thomas S, Sabastian P, Aashal S. Assessment of shoulder function after functional neck dissection and selective neck dissection (levels I, II, III) in patients with carcinoma of tongue: a comparative study. *J Maxillofac Oral Surg.* 2009;8(3):224-229. doi:10.1007/s12663-009-0055-2
12. Cappiello J, Piazza C, Giudice M, De Maria G, Nicolai P. Shoulder disability after different selective neck dissections (levels II-IV versus levels II-V): a comparative study. *Laryngoscope.* 2005;115(2):259-263. doi:10.1097/01.mlg.0000154729.31281.da
13. Givi B, Linkov G, Ganly I, et al. Selective neck dissection in node-positive squamous cell carcinoma of the head and neck. *Otolaryngol Head Neck Surg.* 2012;147(4):707-715. doi:10.1177/0194599812444852
14. Robbins KT, Shaha AR, Medina JE, et al. Consensus statement on the classification and terminology of neck dissection. *Arch Otolaryngol Head Neck Surg.* 2008;134(5):536-538. doi:10.1001/archotol.134.5.536
15. Robbins KT, Clayman G, Levine PA, et al. Neck dissection classification update: revisions proposed by the American Head and Neck Society and the American Academy of Otolaryngology-Head and Neck Surgery. *Arch Otolaryngol Head Neck Surg.* 2002;128(7):751-758. doi:10.1001/archotol.128.7.751
16. Shepard PM, Olson J, Harari PM, Levenson G, Hartig GK. Therapeutic selective neck dissection outcomes. *Otolaryngol Head Neck Surg.* 2010;142(5):741-746. doi:10.1016/j.otohns.2009.12.033
17. Liang L, Zhang T, Kong Q, Liang J, Liao G. A meta-analysis on selective versus comprehensive neck dissection in oral squamous cell carcinoma patients with clinically node-positive neck. *Oral Oncol.* 2015;51(12):1076-1081. doi:10.1016/j.oraloncology.2015.10.005
18. Feng Z, Gao Y, Niu LX, Peng X, Guo CB. Selective versus comprehensive neck dissection in the treatment of patients with a pathologically node-positive neck with or without microscopic extracapsular spread in oral squamous cell carcinoma. *Int J Oral Maxillofac Surg.* 2014;43(10):1182-1188. doi:10.1016/j.ijom.2014.05.018

SUPPORTING INFORMATION

Additional supporting information can be found online in the Supporting Information section at the end of this article.

How to cite this article: Altawil M, Stanisz I, Van Den Berg NH, Sheahan P. Pattern of regional recurrence after selective neck dissection for clinically positive neck in mucosal squamous carcinoma. *Head & Neck.* 2024;1-9. doi:10.1002/hed.27727